

MR Imaging Features of Nipah Encephalitis

Sazilah Ahmad Sarji¹
Basri Johan Jeet Abdullah¹
Khean Jin Goh²
Chong Tin Tan²
Kum Thong Wong³

OBJECTIVE. The newly discovered Nipah virus causes an acute febrile encephalitic illness in humans that is associated with a high mortality. The purpose of this study is to describe the MR imaging findings of Nipah encephalitis.

MATERIALS AND METHODS. MR imaging of the brain was performed in 31 patients with Nipah encephalitis divided into three groups. The first group (14 patients) underwent MR imaging during the acute phase of the illness and the second group (10 patients) during the later phase of the acute illness. The third group consisted of six patients who underwent MR imaging because they experienced neurologic relapse and one patient who had late-onset encephalitis. Spin-echo T1- and T2-weighted sequences and T2-weighted fluid attenuated inversion recovery (FLAIR) sequences were performed. Contrast-enhanced MR imaging was performed in four patients.

RESULTS. The FLAIR sequences revealed abnormalities in all patients studied. MR imaging findings in both the acute and later phases of encephalitis were similar; the main feature of both phases was the presence of discrete high-signal-intensity lesions, measuring 2–7 mm, disseminated throughout the brain, mainly in the subcortical and deep white matter of the cerebral hemispheres. Neither mass effect nor cerebral edema was seen. There was no correlation with the focal neurologic signs, depth of coma, and outcome of the patients. The lesions were attributed to widespread microinfarctions from underlying vasculitis of cerebral small vessels. Features found on MR imaging in relapsed and late-onset encephalitis differed from the features in acute encephalitis in that confluent cortical involvement was the prominent finding in the former, as opposed to discrete focal lesions in the subcortical and deep white matter in the latter.

CONCLUSION. MR imaging is a sensitive and specific diagnostic tool for evaluating Nipah encephalitis.

An outbreak of a deadly encephalitis in humans occurred in Malaysia from late September 1998 to April 1999, involving more than 200 patients with a large number of fatalities [1]. The causative agent was found to be a new virus, later named the Nipah virus after Kampung Sungai Nipah, a village in the state of Negeri Sembilan, Malaysia, where the outbreak occurred. This virus belongs to the paramyxovirus group, a group of enveloped RNA viruses whose members have been shown to cause animal and human infection [2]. It appears to be related to the Hendra virus that was first discovered in 1994 in Australia, where it caused infection among horses and humans [3].

The patients with Nipah encephalitis who were admitted to our medical center were pig

farmers and those who had close contact with pigs. The probable mode of transmission to humans was thought to be close contact with tissue fluids from infected pigs [2]. The Nipah virus causes a febrile encephalitic illness and severe cases were characterized by reduced conscious level, seizures, focal neurologic signs, and brainstem dysfunction. The virus has a high mortality rate in the acute phase, during which patients may undergo rapid neurologic deterioration, coma, and death. Neurologic relapse may also occur. During the initial stages of the outbreak, a number of patients with acute encephalitis who were seen at our center underwent brain CT, but these examinations did not reveal any abnormalities. Hence, MR imaging was performed in these patients at various phases

Received October 20, 1999; accepted after revision January 4, 2000.

¹Department of Radiology, University of Malaya Medical Center, Jalan Universiti, 59100 Kuala Lumpur, Malaysia. Address correspondence to S. A. Sarji.

²Department of Medicine, University of Malaya Medical Center, Jalan Universiti, 59100 Kuala Lumpur, Malaysia.

³Department of Pathology, University of Malaya Medical Center, Jalan Universiti, 59100 Kuala Lumpur, Malaysia.

AJR 2000;175:437–442

0361–803X/00/1752–437

© American Roentgen Ray Society

of the illness to study the patterns of cerebral involvement in Nipah encephalitis, which could help with its diagnosis and perhaps explain the pathogenesis of brain involvement. In this article, we describe the spectrum of brain changes on MR imaging in patients with Nipah encephalitis.

Materials and Methods

MR imaging of the brain was performed in patients with Nipah encephalitis if they came from the known outbreak areas and had close contact with pigs or other animals suspected of being infected and if they had either clinical features of encephalitis (fever, headache, altered sensorium, and focal neurologic signs) or abnormalities in the cerebrospinal fluid (CSF)—in other words, elevated WBC, raised CSF protein levels, or both.

The 31 patients included in this study comprised 23 men, one boy, and seven women. The age range was 15–68 years, with a mean age of 37.5 years. A total of 32 MR imaging examinations was performed in 31 patients. One patient underwent MR imaging in both the acute and later phases of encephalitis. For the purpose of this study, these patients were divided into three groups. MR imaging of the first group (14 patients) was performed in the acute phase (mean duration from onset of acute symptoms to MR imaging, approximately 7 days). The second group consisted of 10 patients who underwent MR imaging in the later phase of encephalitis (mean duration from onset of symptoms to MR imaging, approximately 54 days). In the third group, MR imaging was performed in six patients who had neurologic relapse and in one patient who developed late-onset encephalitis. In this one patient, serology was positive and an earlier MR imaging study had normal findings, but symptoms of encephalitis manifested 10 weeks later. The patient subsequently died and an autopsy was performed.

Severity of coma was assessed by the Glasgow Coma Scale (GCS) and divided into patients with a GCS score of 10 or less and those with a GCS score of more than 10 at the time of MR imaging. MR imaging was performed using a 1.5-T superconducting system, (Vision; Siemens, Erlangen, Germany). The MR imaging sequences were spin-echo T1- (TR/TE, 650/14; one excitation) and T2- (3800/90; two excitations) weighted as well as T2-weighted fluid attenuated inversion recovery (FLAIR) (9000/110; one excitation) sequences. Inversion time was 2500 msec. Images were obtained in the axial plane and coronal plane with a 10-mm slice thickness. T1-weighted contrast-enhanced examination with gadopentetate dimeglumine (0.1 mmol/kg) was performed in four patients. The MR images were evaluated independently by two radiologists.

The extent of brain involvement on MR images was graded as extensive if there were 10 or more focal lesions, lesions that were confluent, or both and as not extensive if there were fewer than 10 focal lesions. The outcome of the patients was

graded as those who recovered with no neurologic deficits, those who recovered with residual neurologic deficits, and those who died.

The patients' blood and CSF were tested against Hendra viral antigen using the IgM capture enzyme-linked immunoabsorbent assay (ELISA) method [2]. CSF was also examined for WBC and protein levels. Statistical analysis was carried out using the chi-square test when appropriate.

Results

Excluding the patients with neurologic relapse and late-onset encephalitis, the main presenting features in the other 23 patients were fever (92%), headache (58%), giddiness (36%), drowsiness (33%), vomiting (25%), and seizures (25%). Focal neurologic signs observed were segmental myoclonus (17%), nystagmus (17%), cerebellar signs (8%), and expressive dysphasia (8%).

MR Imaging Findings in Acute and Later Phases of Encephalitis

MR imaging revealed abnormalities in the brains of all 23 patients in the acute and later phases of encephalitis. Lesions were shown with better clarity and extent on the FLAIR images. All 23 patients had MR imaging findings of small discrete lesions measuring 2–7 mm disseminated in the subcortical and deep white matter of the cerebral hemispheres (Figs. 1 and 2). The number of discrete lesions ranged from as few as two to innumerable. Extensive brain involvement on MR imaging (defined as the

presence of more than 10 focal lesions, lesions that were confluent, or both) occurred in 70% of patients. Most lesions were round, but some appeared as strips (Fig. 3). Lesions in the cerebral cortex were present in 44% of the patients (Fig. 4). Evidence of blood products in the lesions was present on MR imaging in one patient in the later phase of encephalitis (Fig. 5). There was no predilection for a particular site in the brain except for the temporal lobe, which was involved in 30% of the patients (Fig. 6). Lesions in the pons were observed in 22% of the patients. Lesions in the cerebral peduncle were present in three patients (10%). One patient had a focal lesion in the cerebellum. There was a lack of edema around the lesions, no mass effect, and an absence of generalized cerebral edema in all patients. Hyperintense signal intensity in the subarachnoid spaces on FLAIR images was not present in any of the patients, and contrast-enhanced MR imaging performed in four patients with acute encephalitis showed neither enhancement of lesions nor significant enhancement of the meninges.

No correlation appears to exist between focal neurologic signs and findings on MR imaging. Of the 23 patients, five patients had nystagmus, cerebellar signs, or both, and MR imaging revealed posterior fossa lesions in three of these patients. However, MR imaging also revealed posterior fossa lesions in five of the 18 patients who had no evidence of nystagmus or cerebellar signs. Segmental myoclonus involving the diaphragm (five pa-

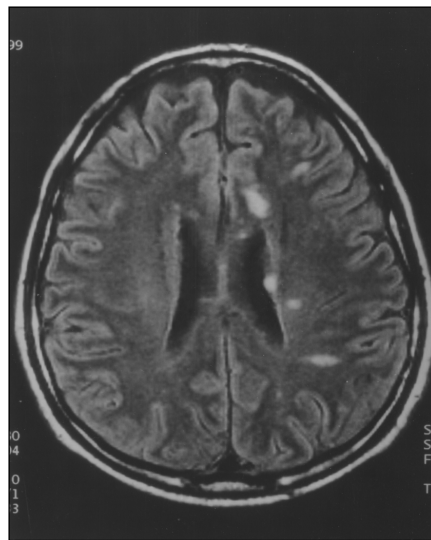


Fig. 1.—44-year-old man with acute Nipah encephalitis. Axial fluid attenuated inversion recovery MR image shows multiple discrete lesions in subcortical and deep white matter of cerebrum.

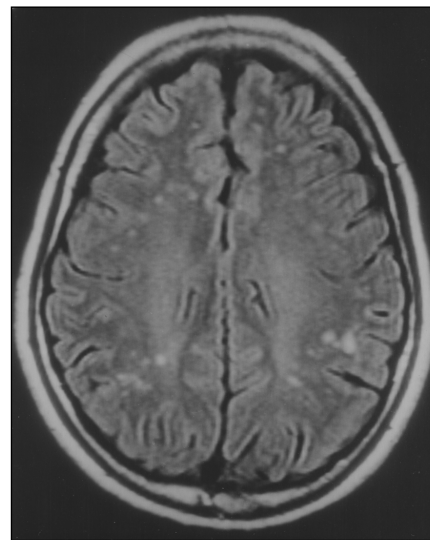


Fig. 2.—53-year-old man with acute Nipah encephalitis. Axial fluid attenuated inversion recovery MR image shows disseminated discrete round lesions in white matter.

MR Imaging of Nipah Encephalitis

Fig. 3.—26-year-old man with early Nipah encephalitis. Axial fluid attenuated inversion recovery MR image shows subcortical lesion, which appears as strip in early Nipah encephalitis (arrowhead).

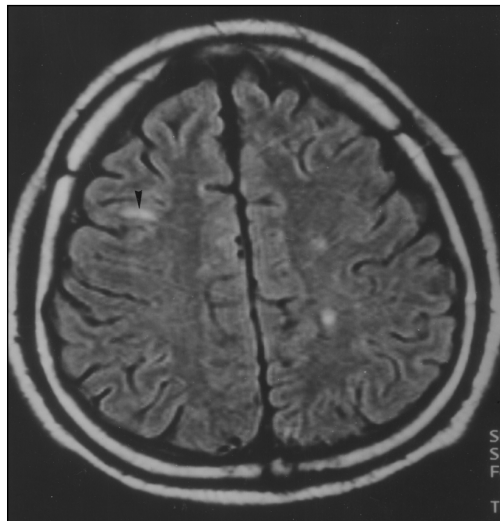


Fig. 4.—45-year-old patient with acute Nipah encephalitis. Axial fluid attenuated inversion recovery MR image shows lesions in gray matter (arrowheads).

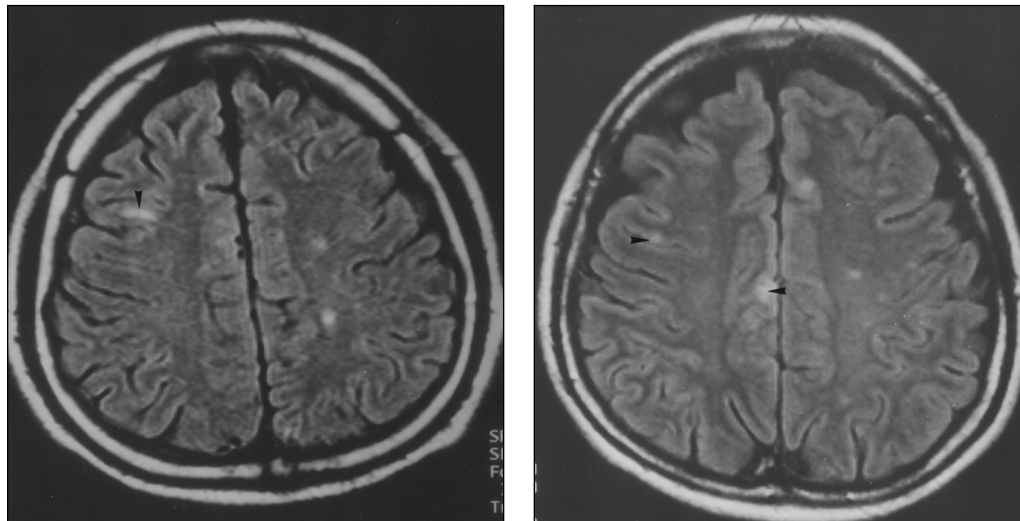
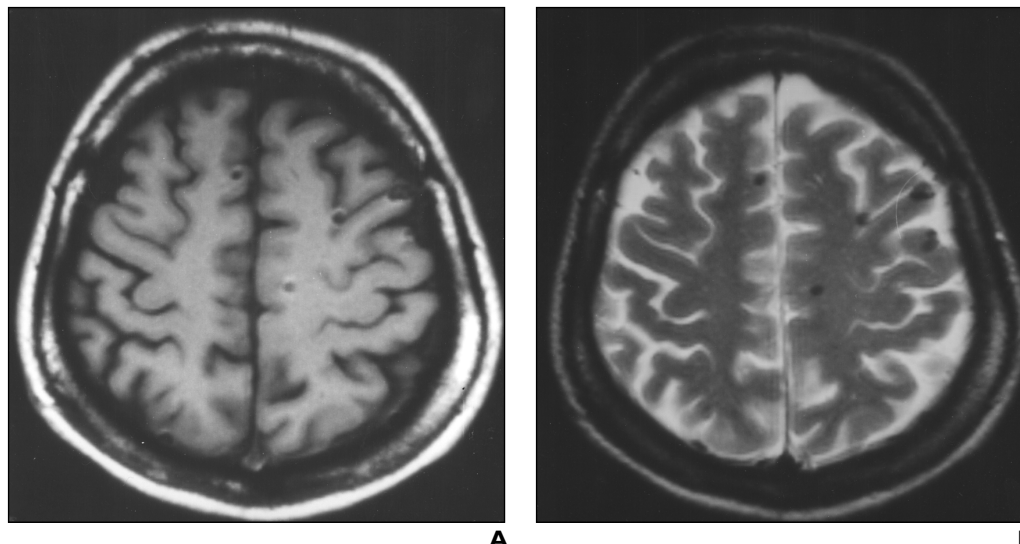


Fig. 5.—40-year-old woman in the later phase of acute Nipah encephalitis. **A** and **B**, T1-weighted (**A**) and T2-weighted (**B**) spin-echo MR images show discrete round lesions with MR signal of old blood products.



tients), anterior part of the neck (one patient), and the limbs (two patients) was observed in five patients and expressive dysphasia in one patient. No corresponding cerebral lesions were found in patients with segmental myoclonus. However, the MR imaging examination did not include the spinal cord. Small focal lesions in the subcortical and deep white matter of the cerebral hemispheres, cerebral peduncles, and cerebellum were present on MR imaging in the patient with expressive dysphasia, and these findings did not correspond with this focal sign.

Of the 23 patients, 16 (70%) tested positive for antibodies against Hendra viral antigen in the blood. Abnormal CSF findings were

found in 15 patients (65%), and 10 patients (43%) tested positive for antibodies against the viral antigen in their CSF. Eleven patients had a GCS score of 10 or less, and 12 patients had a GCS score of more than 10 at the time of MR imaging. No correlation was observed between the extent of brain involvement on MR imaging and the severity of coma ($p < 0.05$). Eleven patients recovered without neurologic deficits, seven patients recovered with some neurologic deficits, and five patients died. The extent of brain involvement on MR imaging and the outcome of the patients did not correlate ($p < 0.05$).

The MR imaging findings in the acute phase did not differ from those in the later

phase of the illness. MR imaging was performed in the acute phase and in the later phase of the illness in one patient. The findings in the acute phase were multiple small focal lesions in the subcortical and deep white matter throughout the cerebral hemispheres, small focal lesions in the pons, and confluent involvement of the right temporal lobe. A repeated MR imaging study 7 weeks later showed slight improvement in the temporal lobe, but lesions in the rest of the brain remained the same. No new lesions were noted.

MR Imaging Findings in Relapse Cases

Six patients who recovered from Nipah encephalitis underwent MR imaging because

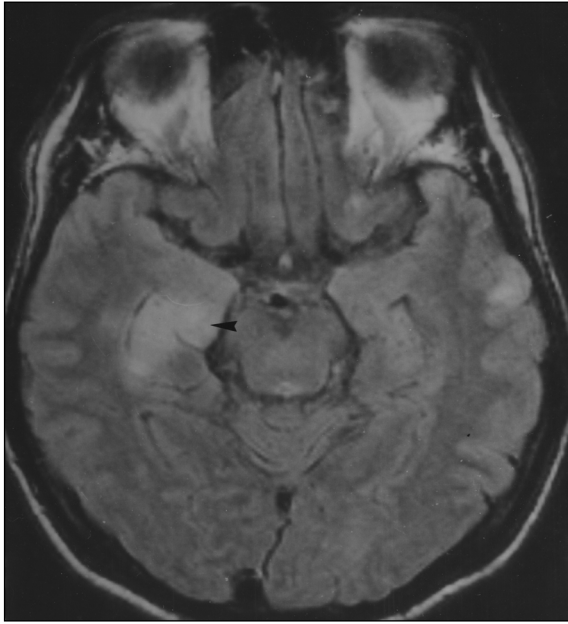


Fig. 6.—40-year-old man with acute Nipah encephalitis. Fluid attenuated inversion recovery MR image shows confluent involvement of temporal lobe (arrowhead).

ronal death, neuronophagia, parenchymal inflammation, and perivascular cuffing, typically encountered in a primary viral encephalitis. Neither vasculitis nor microinfarction was evident.

Discussion

MR imaging is the imaging method of choice for examining viral encephalitis, being more sensitive than CT [4]. New techniques in MR neuroimaging have resulted in better detection and visualization of lesions in brain parenchyma. Intracranial pathology can often be seen sooner and in greater detail and extent using the FLAIR sequence. Because the FLAIR sequence produces heavily T2-weighted images with suppression of CSF signal, lesions at the periphery of the brain, around the basal cisterns, in the brainstem, at gray-white interfaces, and in the periventricular region become more conspicuous [5]. FLAIR images have been shown to yield particularly high lesion contrast in encephalitic lesions [6]. In meningitis, high signal intensity is revealed along the sulci of the brain on the FLAIR sequence [7]. We found MR imaging, particularly using the FLAIR sequence, sensitive in the diagnosis of Nipah encephalitis; abnormalities were detected in 100% of the patients with this imaging technique. MR imaging was shown to be more sensitive than blood serology, CSF examination, and CSF serology in confirming central nervous system (CNS) involvement of the Nipah infection.

of recurrence of neurologic dysfunction. Unfortunately, they had no previous MR imaging during the initial acute episode. One patient developed an isolated left third nerve palsy, and MR imaging revealed a focal lesion in the region of the oculomotor nucleus in the left midbrain. The other five patients had neurologic relapse, which included recurrent headache or seizures and cognitive dysfunction. MR imaging showed patchy areas of confluent cortical involvement, mainly in the cerebral hemispheres (Figs. 7 and 8).

One patient was found to be seropositive early in the outbreak but was asymptomatic with no abnormal findings on MR imaging at that time. However, she presented 10 weeks later with frontal headache and seizures. MR imaging revealed confluent cortical involvement of the right frontal lobe (Fig. 9). She deteriorated rapidly 36 hr after the second MR imaging study and died. A brain-only autopsy showed necrosis and acute inflammation of the cortex and adjacent white matter, mainly in the right frontal lobe. There was evidence of neu-

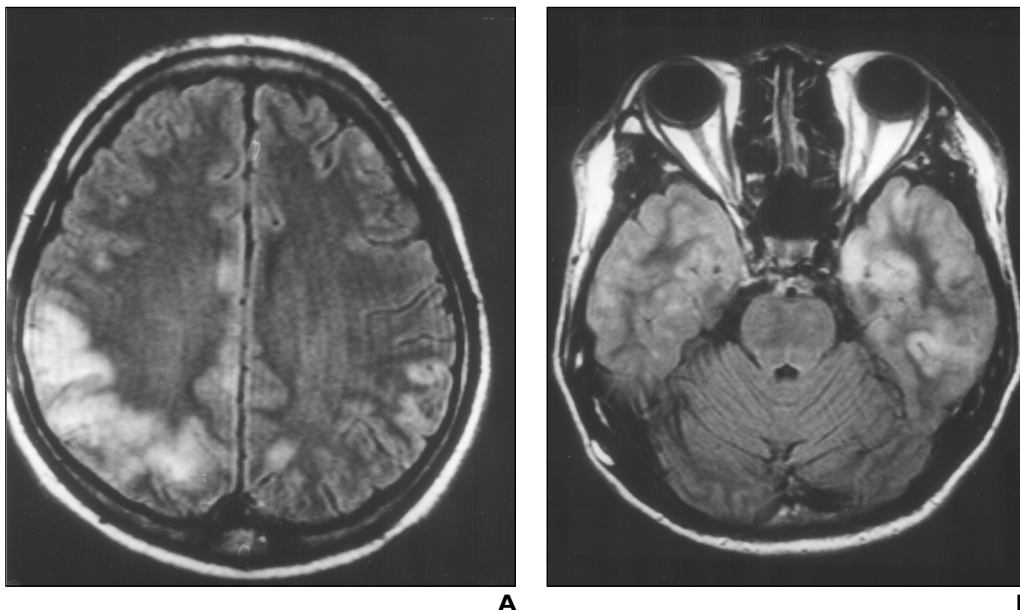
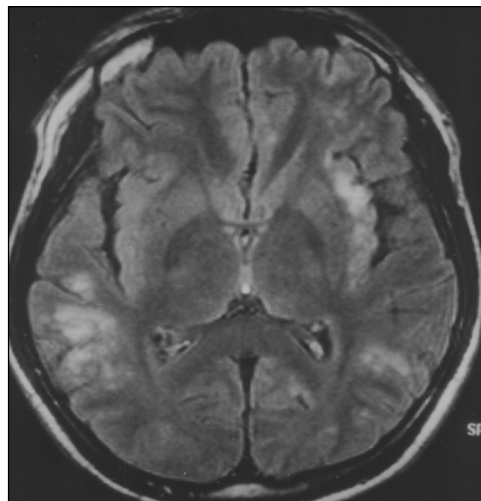


Fig. 7.—28-year-old man with relapsed Nipah encephalitis. **A** and **B**, Fluid attenuated inversion recovery MR images through parietal lobes (**A**) and temporal lobes (**B**) show confluent cortical involvement.

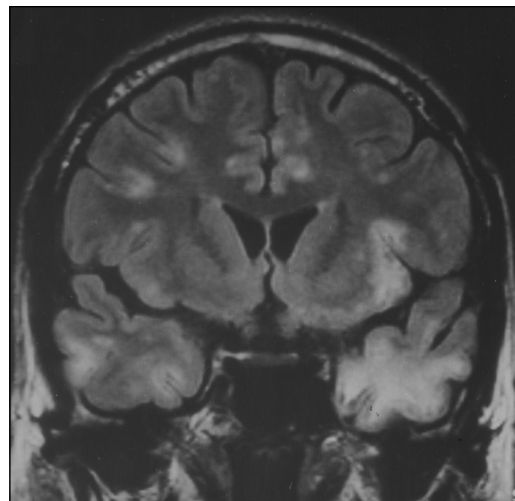
MR Imaging of Nipah Encephalitis

Fig. 8.—33-year-old man with relapsed Nipah encephalitis.

A and B, Axial (**A**) and coronal (**B**) MR images show distinct feature of confluent gray matter involvement, well seen on fluid attenuated inversion recovery sequence.



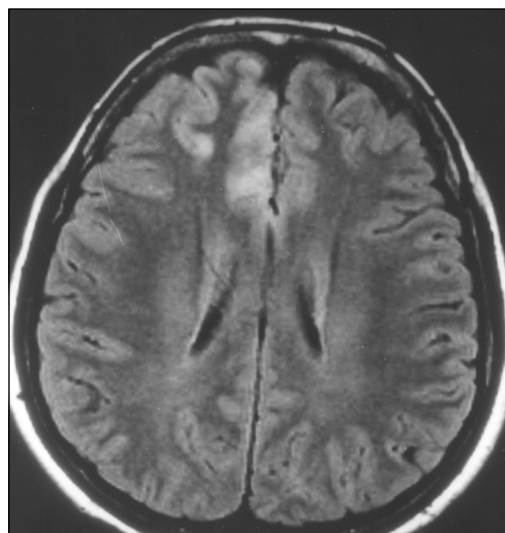
A



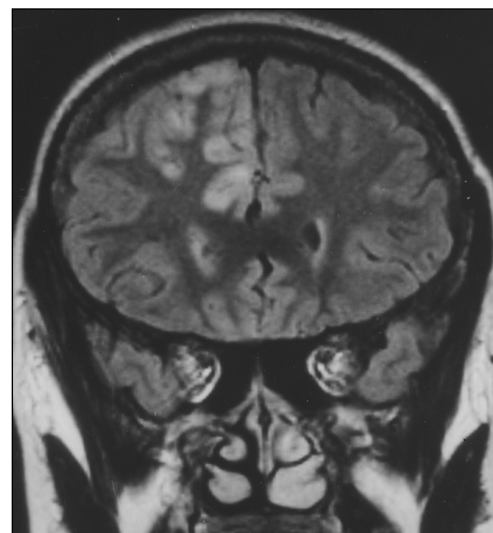
B

Fig. 9.—31-year-old woman with late-onset Nipah encephalitis.

A and B, Axial (**A**) and coronal (**B**) fluid attenuated MR images show confluent cortical involvement, similar to that seen in patient with relapsed Nipah encephalitis, in right frontal lobe.



A



B

The findings on MR imaging in Nipah encephalitis were predominantly small focal lesions in the subcortical and deep white matter and, to a lesser extent, in the gray matter. There was a paucity of mass effect and cerebral edema, even in cases in which innumerable lesions were scattered throughout the brain. On reviewing the literature, these features differed from the MR imaging descriptions of other sporadic endemic viral encephalitides. Because of the association of those affected with pigs, the outbreak of encephalitis in Malaysia was initially thought to be caused by Japanese encephalitis. The MR imaging features of Japanese encephalitis are described as high-signal-intensity areas on T2-weighted and low-signal-intensity areas on T1-weighted images, involving

the white matter, brainstem, basal ganglia, and, classically, the thalami bilaterally [8, 9]. Hemorrhage into the thalami occurs with Japanese encephalitis, and MR imaging reveals the signal intensities of the blood products on corresponding T1- and T2-weighted images [10]. The MR imaging findings in all our patients were clearly not similar to Japanese encephalitis. In Eastern equine encephalitis, focal lesions in the basal ganglia and thalami are described as the characteristic features on MR imaging [11]. Again, these were not the MR imaging findings in our patients. Our MR imaging findings also differed from those of herpes simplex encephalitis, for which the classic description is early edematous changes with confluent high-signal areas on T2-weighted MR images in the

temporal lobe and limbic system, which later frequently hemorrhages [4]. Thus, we believe the MR imaging features in Nipah encephalitis are unique.

Autopsy was not performed in patients from our series who died from acute Nipah encephalitis. However, the main pathologic findings from autopsies of the brains of other patients who died of acute Nipah encephalitis was vasculitis-induced thrombosis, which in turn caused widespread microinfarctions throughout the brain. There was also direct neuronal involvement as evidenced by the presence of occasional viral inclusion bodies [2]. We believe the small focal lesions in the subcortical and deep white matter and cerebral cortex revealed on MR imaging corre-

late with the microinfarcts found at autopsy of the brains of patients who died of acute Nipah encephalitis. Therefore, MR imaging findings in the acute phase of the infection do support the suggestion that in Nipah encephalitis, the pathogenesis is largely a vasculitic process that involves small vessels, resulting in focal disseminated areas of ischemia and microinfarctions in the CNS. These appear as high-signal-intensity lesions in the white and gray matter of the brain on T2-weighted and FLAIR MR images. Our observation of the lack of mass effect and cerebral edema on MR imaging correlated well with the findings of normal CSF opening pressures on lumbar puncture in most patients. The explanation for this observation may be that the vasculitic process, however extensive, was not severe enough to result in significant cerebral edema, and raised intracranial pressure.

Correlation was poor between focal neurologic signs and MR imaging findings. This may be because MR imaging findings reflected white matter microinfarctions rather than neuronal involvement by the virus in the gray matter of the brain. Alternatively, very small microinfarcts may be undetectable on MR imaging. Correlation was also poor between severity of neurologic status or the depth of coma and MR imaging findings. Coma is likely to be a result of direct involvement of the reticular formation, in which case MR imaging was unable to reveal any abnormalities, as well as widespread microinfarcts and ischemia in the brain. There was, in addition, lack of correlation between patient outcome and MR imaging findings in the brain. Again this is likely because the MR imaging findings largely reflect widespread microinfarcts and ischemia, whereas outcome of the patients is probably mainly related to the extent of direct neuronal involvement.

The widespread distribution of lesions throughout the brain in Nipah encephalitis suggests that infection in the CNS is likely to be via a hematogenous route. Presumably, after initial acquisition of the virus by the host, viremia develops and spreads to the blood vessels of the CNS. Although our cases showed no predilec-

tion for a particular site in the brain, involvement of the uncus of the temporal lobe was observed in 30% of patients. This allows us to postulate another possible route of entry of the virus into the brain: direct inhalation of the virus through the nasal airway, along the olfactory bulb and tract into the uncus. This route of entry has also been proposed in herpes simplex encephalitis [12]. Because it is only found in a few patients, the nasal route into the CNS, if it occurs, probably only plays a minor role in Nipah encephalitis.

There appears to be no significant difference in the MR imaging findings in acute and later phase encephalitis as was shown in one patient from our series. In this patient, MR imaging showed no significant change or improvement of lesions and no evidence of new lesions. These findings correlated well with neurologic improvement in the patient. The MR imaging findings in patients with relapse and late-onset encephalitis were markedly different from the findings of early Nipah encephalitis. The distinct confluent involvement of the cortex on MR imaging in these patients suggests a different pathologic mechanism in relapse and late-onset Nipah encephalitis. It is interesting to note the resemblance of these findings with the MR imaging findings reported in a case of late-onset fatal meningoencephalitis caused by the Hendra virus [13]. Because the Nipah virus is also a paramyxovirus related to the Hendra virus, there may be similarities in the pathogenesis of late-onset and relapsed Nipah encephalitis and Hendra encephalitis. The findings in the brain of our patient who died from late-onset disease were typical of primary viral encephalitis rather than disseminated microinfarcts of acute Nipah encephalitis. This appears to correlate well with findings on MR imaging. Further work will be needed to unravel the pathogenesis of early and relapsed or late-onset Nipah encephalitis.

In summary, this new infection has features on cerebral MR imaging that appear distinct from MR imaging descriptions of other primary viral encephalitides. The MR imaging features of late-onset disease and relapsed encephalitis were different from early encephalitis. We conclude that MR imaging is a sensitive and specific diagnostic tool for Nipah encephalitis.

Acknowledgments

We thank all the clinical and nursing staff of University Malaya Medical Center; Mohd Rani Jusoh from Kuala Lumpur Hospital, and Termizi Thayaparam and H. T. Chong from Seremban Hospital for referring three of the patients; and Thomas G. Ksiazek and his team from the Centers for Disease Control and Prevention, Atlanta, for performing the serologic studies.

References

- Centers for Disease Control and Prevention. Outbreak of Hendra-like virus: Malaysia and Singapore—1998–1999. *MMWR CDC Surveill Summ* **1999**;48:265–269
- Chua KB, Goh KJ, Wong KT, et al. Fatal encephalitis due to Nipah virus among pig farmers in Malaysia. *Lancet* **1999**;354:1257–1259
- Selvey L, Wells RM, McCormack JG, et al. Infection of humans and horses by a newly described morbillivirus. *Med J Aust* **1995**;162:642–645
- Hansman Whiteman ML, Bowen BC, Donovan Post MJ, Bel MD. Intracranial infection. In: Atlas SW, ed. *Magnetic resonance imaging of the brain and spine*, 2nd ed. Philadelphia: Lippincott-Raven, **1996**:707–772
- De Coene B, Hajnal JV, Gatehouse P, et al. MR of the brain using fluid-attenuated inversion recovery (FLAIR) pulse sequences. *AJNR* **1992**;13:1555–1564
- Tsuchiya K, Inaoka S, Mizutani Y, Hachiya J. Fast fluid-attenuated inversion recovery MR of intracranial infections. *AJNR* **1997**;18:909–913
- Adams JG, Melhem ER. Clinical usefulness of T2-weighted fluid-attenuated inversion recovery MR imaging of the CNS. *AJR* **1999**;172:529–536
- Abe T, Kojima K, Shoji H, et al. Japanese encephalitis. *J Magn Reson Imaging* **1998**;8:755–761
- Shoji H, Kida H, Hino H, et al. Magnetic resonance imaging findings in Japanese encephalitis: white matter lesions. *J Neuroimaging* **1994**;4:206–211
- Kumar S, Misra UK, Kalita J, Salwani V, Gupta RK, Gujral R. MRI in Japanese encephalitis. *Neuroradiology* **1997**;39:180–184
- Deresiewicz RL, Thaler SJ, Hsu L, Zamani AA. Clinical and neuroradiographic manifestations of eastern equine encephalitis. *N Engl J Med* **1997**;336:1867–1874
- Grossman RI, Yousem DM. Infectious and non-infectious inflammatory diseases of the brain. In: *Neuroradiology: the requisites*. St. Louis: Mosby—Year Book **1994**:181–184
- O'Sullivan JD, Allworth AM, Paterson DL, et al. Fatal encephalitis due to novel paramyxovirus transmitted from horses. *Lancet* **1997**;349:93–95